

Name: _____ Alter: _____ Beruf: _____

Diagnose: _____

Sichtbefund: _____

1. Rumpf-Schultergürtel

Muskel	re.	li.	ASTE	Muskel	re.	li.	ASTE
1. M. trap. ELEVATION			Sitz	4. M. levator scapulae			s. 1.
2. M. trap. ADDUKTION			BL	5. Mm. rhomboidei			s. 2.
3. M. trap. DEPRESSION			BL	6. M. serratus ant.			RL
				7. M. pectoralis minor			RL

2. Schultergürtel – Oberarm

Muskel	re.	li.	ASTE	Muskel	re.	li.	ASTE
1. M. infraspinatus			BL	5. M. subscapularis			BL
2. M. teres minor				6. M. teres major			
3. M. supraspinatus			Sitz	7. M. coracobrachialis			Sitz
4. M. deltoideus ABD				8. M. deltoideus FLEX			
				9. M. deltoideus EXT.			BL
				10. M. latissimus dorsi			
				11. M. deltoideus p. spin.			RL

3. Rumpf – Oberarm

Muskel	re.	li.	ASTE	Muskel	re.	li.	ASTE
1. M. pectoralis major			RL	2. M. latissimus dorsi			s.o.

4. Schultergürtel – Unterarm

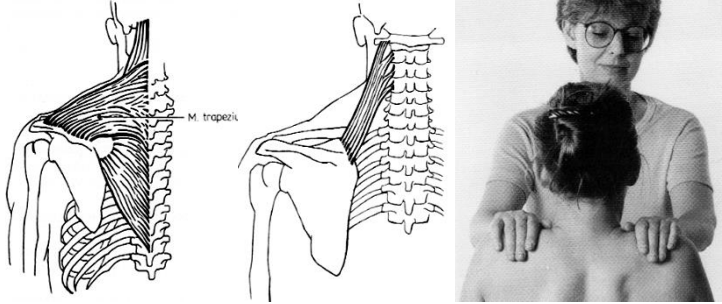
Muskel	re.	li.	ASTE	Muskel	re.	li.	ASTE
1. M. biceps brachii			Sitz	2. M. triceps brachii			BL

5. Zusammenfassung

Muskelfunktionsprüfung

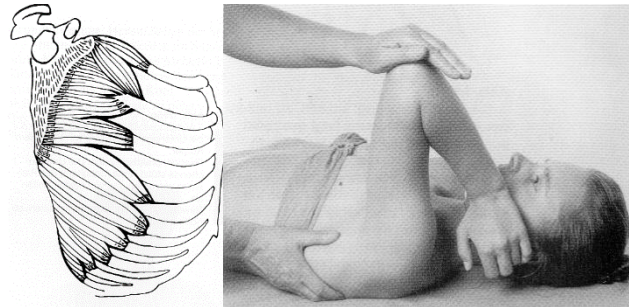
M. trapezius pars descendens und M. levator scapulae

- Haupt- / Testfunktion: Elevation
- ASTE: 5,4,3: Sitz, 2,1,0: BL



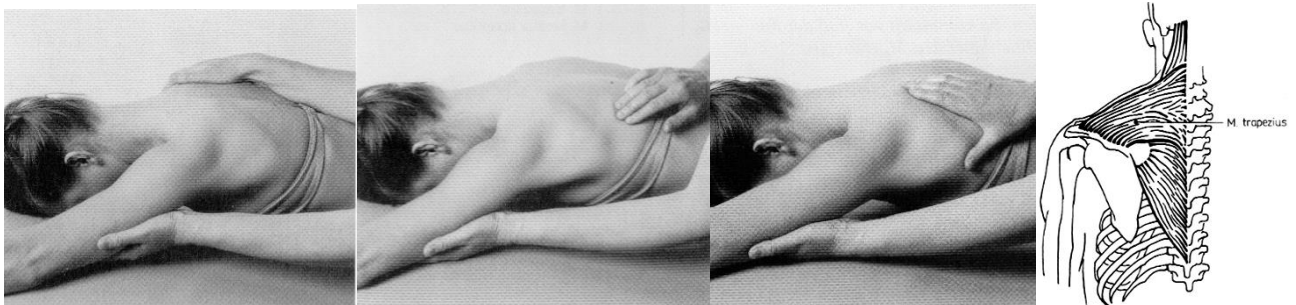
M. serratus anterior

- Haupt- / Testfunktion: ABDuktion mit Rotation des ang. Inferio
- ASTE: 5,4,3: RL, 2,1,0: Sitz



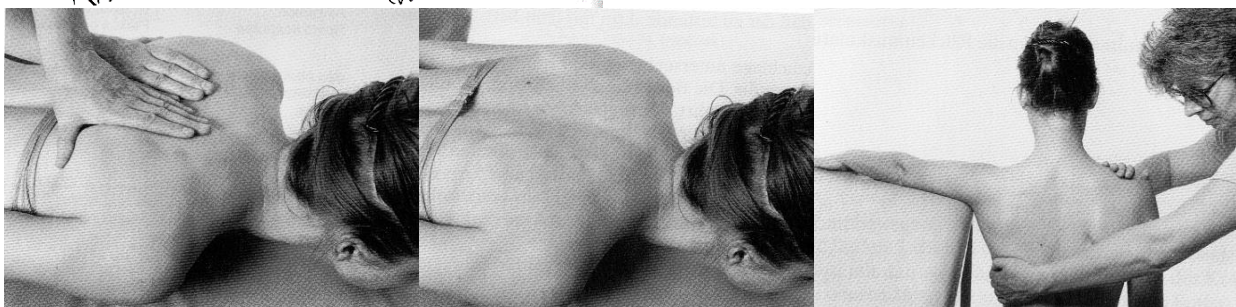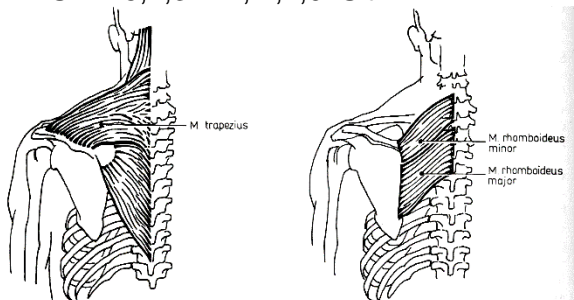
M. trapezius pars ascendens

- Haupt- / Testfunktion: Depression
- ASTE: BL



M. trapezius und Mm. rhomboidei

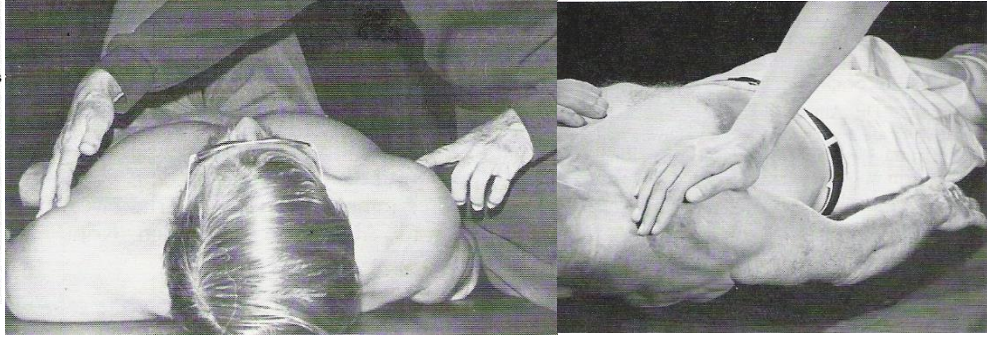
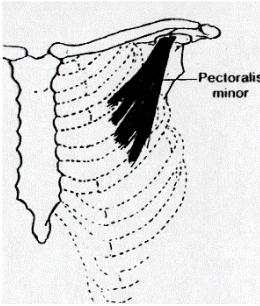
- Haupt- / Testfunktion: ADDUKTION der Scapula
- ASTE: 5,4,3: RL, 2,1,0: Sitz



M. pectoralis minor

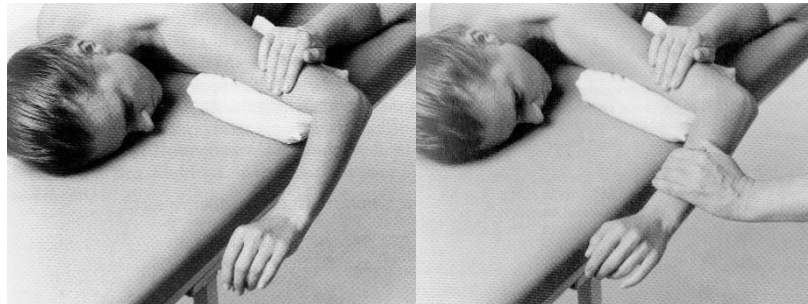
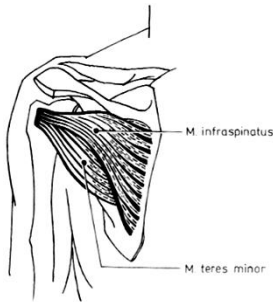
⇒ DEHNFÄHIGKEIT!!!

- Haupt- / Testfunktion: 1. Kippung der Scapula nach ventral, caudal
- 2. Anhebung des Thorax
- ASTE: RL



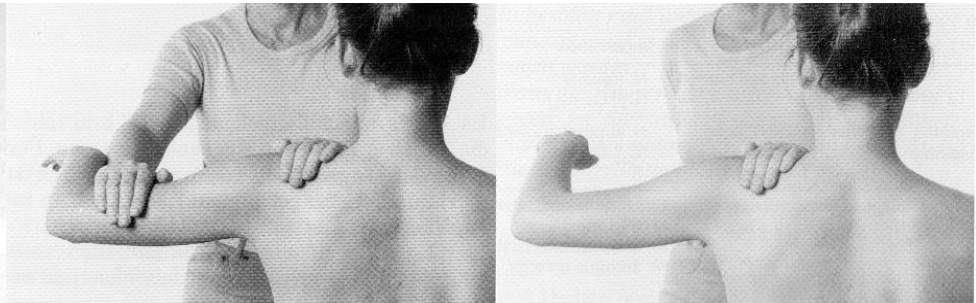
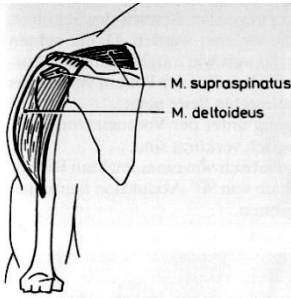
M. infraspinatus und M. teres minor

- Haupt- / Testfunktion: ARO
- ASTE: BL



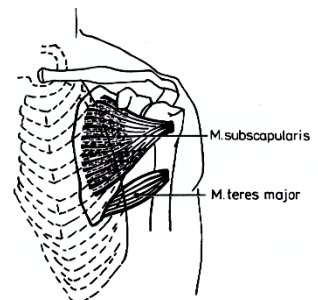
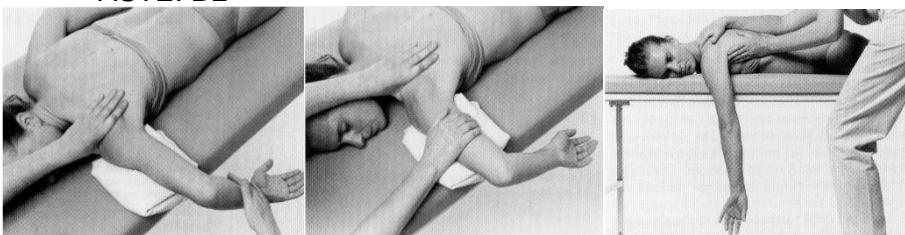M. supraspinatus und M. deltoideus pars acromialis

- Haupt- / Testfunktion: ABD
- ASTE: 5,4,3: Sitz; 2,1,0: RL



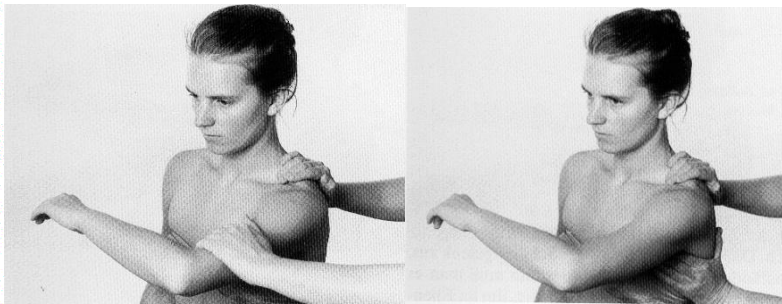
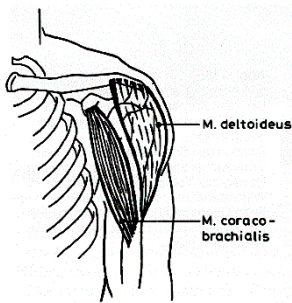
M. subscapularis und M. teres major

- Haupt- / Testfunktion: IRO
- ASTE: BL



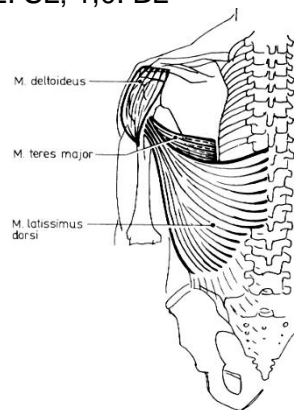
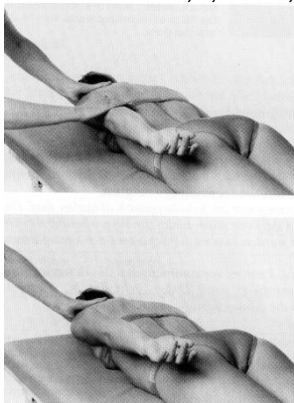
M. coracobrachialis und M. deltoideus pars clavicularis

- Haupt- / Testfunktion: FLEX
- ASTE: 5,4,3: Sitz; 2: SL; 1,0: RL



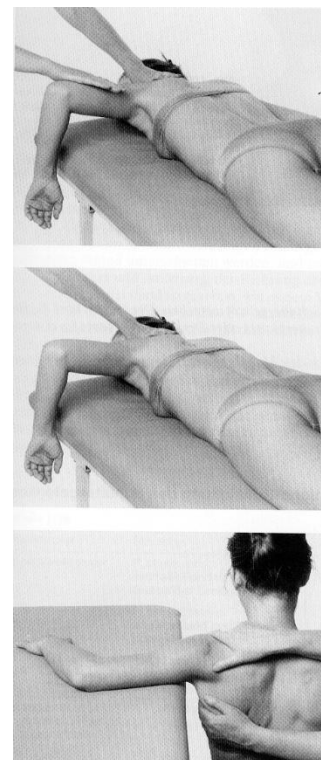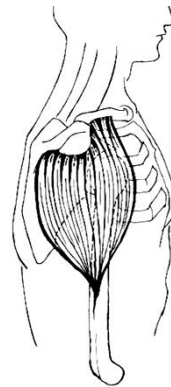M. deltoideus pars spinalis und M. latissimus dorsi

- Haupt- / Testfunktion: EXT
- ASTE: 5,4,3: BL; 2: SL; 1,0: BL



M. deltoideus pars spinalis

- Haupt- / Testfunktion: horizontale ABD
- ASTE: 5,4,3: BL; 2,1,0: Sitz



M. pectoralis major

- Haupt- / Testfunktion: horizontale ADD
- ASTE: 5,4,3: RL; 3,2,1,0: Sitz

